

Commentary

## Constraining the cortical face network by neuroimaging studies of acquired prosopagnosia

Bruno Rossion

*University of Louvain, Belgium*

Received 19 September 2007; revised 19 October 2007; accepted 27 October 2007  
Available online 12 November 2007

This commentary focuses on the past and present contributions of the study of acquired prosopagnosia to our understanding of the cortical face network presented by Alunit Ishai. By themselves, these studies have for long illustrated the distributed nature of face processing and have revealed the dominant role of the right hemisphere in this function. In combination with fMRI, recent studies of brain damaged prosopagnosic patients suggest a direct pathway from early visual areas to the high level right ‘FFA’ area, bypassing the ‘OFA’. They also underline the necessary role of both the ‘OFA’ and ‘FFA’ in the right hemisphere, and their putative reentrant interactions, for the elaboration of a full individual face percept. These neuropsychological observations refine and constrain the functional organization of the core regions of the cortical face network.

I largely agree with Alunit Ishai's view that face processing is subtended by a (sub)cortical network in the human brain. In fairness, this proposal was emphasized by the very first neuroimaging studies in this field (Sergent et al., 1992) and has only rarely been challenged in favor of a strict localizationist view (e.g. Kleinschmidt and Cohen, 2006). Yet, as rightly pointed out by Ishai, there has certainly been too much emphasis on the area showing a preferential response to faces in the middle fusiform gyrus (MFG), the so-called ‘fusiform face area’ (‘FFA’) (Kanwisher et al., 1997), at the expense of other areas. Processes carried out in the ‘FFA’, in particular in the right hemisphere, are without a doubt of fundamental importance for face processing, but the ‘FFA’ alone cannot carry out the whole function without “a little help from its friends” (Tovée, 1998).

Because most face processes are efficient, fast, and do not require extensive learning, it is easy to forget that face processing as a whole is indeed an extremely complex function, hence the large amount of (sub)cortical structures being involved. This degree of complexity already concerns the extraction of a full individual percept (the function of the “core” visual regions of the face network; Ishai, this issue; Haxby et al., 2000). Indeed, the face is a complex 3D visual stimulus made of multiple features, external and internal, which vary in local shape and surface (texture and color) information. These features form a particular configuration

that helps in categorizing the stimulus as a face and performing finer-grained categorizations (e.g. identifying a specific individual). These diagnostic cues and their relationships change constantly for an observer with the viewing conditions (distance, viewpoint, lighting...) and also undergo rapid and slow modifications (expression, aging...), such that generalizing across these changes is a real challenge for our face processing system.

The complexity of face perception is dramatically revealed through the observation of patients who have lost this ability following brain damage, despite an intact visual system and a preserved ability to recognize people through other modalities. This rare deficit in face recognition has attained considerable notoriety in the neuropsychological literature since the early clinical observations (e.g. Quaglino and Borelli, 1867) and the introduction of the term ‘prosopagnosia’ (Bodamer, 1947).

Precisely, the present commentary refers to the study of acquired prosopagnosia, by itself and in combination with functional imaging, both to complement and qualify Ishai's present contribution. My commentary will be limited to the “core” regions of the cortical face processing network: the ‘FFA’, ‘OFA’, pSTS, to which I will add the anterior temporal pole of the right hemisphere.

It should be reminded that it is the study of prosopagnosia, followed by the recording of single neurons in the monkey infero-temporal cortex (Gross et al., 1972), that constitutes the root of our understanding of the neural underpinnings of face processing. In particular, rather than supporting a strict localization of face processing, studies of prosopagnosic patients have illustrated the distributed nature of this function (e.g. Bauer, 1986; Damasio et al., 1990). Early on, these studies also revealed a dominant role of the right hemisphere in face perception (Hécaen and Angelergues, 1962), an observation that has been supported by multiple sources of evidence and which is curiously neglected by Ishai (this issue).

Acquired prosopagnosia is both a homogenous and heterogeneous disorder. On the one hand, a common aspect of all these patients is the inability to recognize familiar faces, with deficits concerning high-level perceptual face processes (Farah, 1990). On the other hand, the underlying causes, the degree of severity of the impairment, and the associated deficits are highly variable (Schweich and Bruyer, 1993; Sergent and Signoret, 1992). The lesions causing prosopagnosia concern by and large the occipito-

---

*E-mail address:* [bruno.rossion@psp.ucl.ac.be](mailto:bruno.rossion@psp.ucl.ac.be).

Available online on ScienceDirect ([www.sciencedirect.com](http://www.sciencedirect.com)).

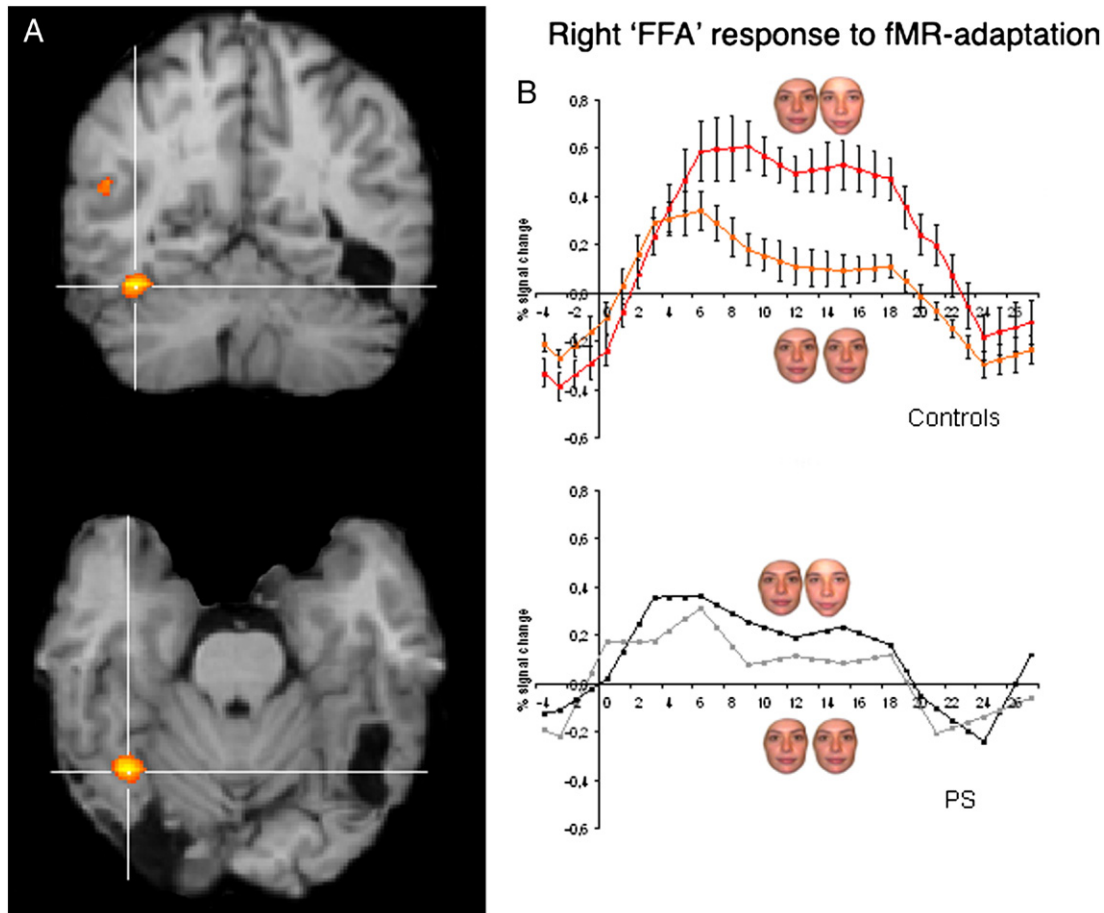


Fig. 1. (A) Activation of the right 'FFA' (and pSTS on the coronal view) in the brain-damaged prosopagnosic patient PS despite a lesion to the right inferior occipital cortex and no evidence of face-preferential response in posterior areas (i.e. no 'OFA', Rossion et al., 2003; illustrated data from 'face localizer' runs in Sorger et al., 2007). Note that the left hemisphere lesion encompasses the left 'FFA'. (B) When different face stimuli are presented, the normal 'rFFA' shows a larger response than when identical face stimuli are repeated (fMRI adaptation, e.g. Grill-Spector and Malach, 2001). This effect is not found significantly in PS 'rFFA', in line with her prosopagnosia (Schiltz et al., 2006; Dricot et al., in press).

temporal pathway with a right hemispheric dominance (Damasio et al., 1982; Sergent and Signoret, 1992). More recent analyses have compared the lesion(s) localization in cases of prosopagnosia to the putative localization of the 'OFA' and 'FFA', indicating that *both* of these areas in the right hemisphere, but not the pSTS, are usually involved (Barton et al., 2002; Bouvier and Engel, 2006). A number of prosopagnosic patients with damage to the anterior temporal cortex, either as a result of a trauma (e.g. Bukach et al., 2006) or neurodegenerative disorders (e.g. Gainotti et al., 2003) have also been reported, suggesting an important role of this region in the cortical face network, a missing component of Ishai's adapted model (but see Haxby et al., 2000). The right anterior temporal cortex is usually neglected by fMRI studies of face processing because there is indeed too much emphasis on the 'FFA', with few studies recording up to the inferior anterior temporal pole. Moreover, because the fMRI signal is most sensitive to magnetic susceptibility artifacts in this region, studies that do not rely on EPI and spiral based imaging sequences which can compensate for the signal drop-out (e.g. spiralscanning, Glover and Law, 2001) may miss important face-related activations in these areas.

Hence, in complement to neuroimaging, these studies of prosopagnosic patients indicate that the areas of the 'OFA', 'FFA', anterior IT (but not the pSTS) are *necessary* for normal face

identity processing. However, contrary to what is stated by Ishai in her commentary, the fact that bilateral lesions are often found in cases of prosopagnosia, such as PS (Rossion et al., 2003; Sorger et al., 2007) does not suggest that bilateral activation is necessary for face recognition: contrary to a left unilateral lesion<sup>1</sup>, a right hemispheric lesion is both sufficient and necessary to cause the prosopagnosic deficit (Barton et al., 2002; Bouvier and Engel, 2006; Sergent and Signoret, 1992; Michel et al., 1989).

Despite bringing some fundamental and complementary information about the neural basis of face processing, the study of prosopagnosic patients by itself is limited with respect to functional imaging studies, mostly because of the variability of functional impairments and lesion localizations of the patients, preventing to draw a precise map of the structures involved. Moreover, the degree of variability in the localization of these areas in the normal brain makes it difficult to ascertain whether a damage to the fusiform gyrus encompasses the 'FFA' or not from structural imaging data alone (e.g. Barton et al., 2002). Finally, brain areas

<sup>1</sup> Only two prosopagnosic patients with unilateral left lesions have been reported so far (Mattson et al., 2000, left handed case; Wright et al., 2006), notwithstanding the fact that in these cases the functional integrity of the right hemisphere is unknown (see Wright et al., 2006).

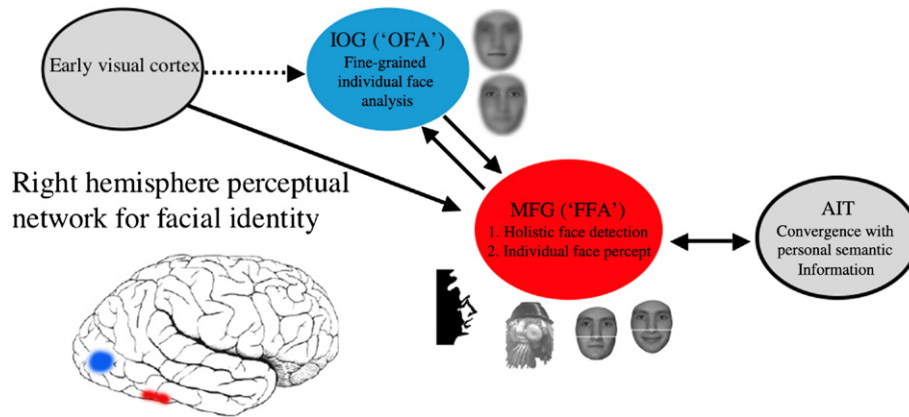


Fig. 2. Reformulating the neuro-functional organization of individual face perception in the human brain. Following early visual analysis, visual stimuli are categorized as whole faces in the middle fusiform gyrus (MFG), leading to face preferential activation ('FFA'). This direct pathway is independent from the posteriorly located 'OFA', which may or may not also show face preferential response from early visual inputs (dotted line). Unlike strict hierarchical models postulating a necessary early stage in the 'OFA', this scheme can account for the 'FFA' activation without 'OFA' such as observed in prosopagnosic patients PS and DF (Rossion et al., 2003; Steeves et al., 2006). The global but crude representation of the face stimulus in the MFG is then refined through reentrant interactions with the IOG, leading or increasing the face preferential activation at this level ('OFA'). Processes in the 'OFA' area, where neurons have smaller receptive fields, are tuned to finer-grained analyses of features (e.g. mouth, eyes ...). This refinement of the representation allows the extraction of a full percept of an individual face in both areas, with the 'rFFA' representing individual faces holistically (Schiltz and Rossion, 2006).

may appear intact on structural images while being functionally depressed because of a lack of input from damaged areas (neural diaschisis, Price et al., 2001).

These points highlight the advantage of testing prosopagnosic patients in combination with *functional* imaging to inform about the neuro-functional connectivity of the face network. Brain-damaged prosopagnosic patients who present a relatively isolated face perception disorder are extremely rare, but it is currently possible to design fMRI studies where the data from a *single* patient, compared to a group of normal controls, can have enough power to be highly informative and move the field forward. For instance, the prosopagnosic patient PS has a large right IOG lesion, with no 'OFA' activation, but nevertheless presents a preferential activation for faces in the right MFG in the normal range ('rFFA'; Rossion et al., 2003). This observation seriously constrains an important aspect of the neuro-functional model proposed by Ishai (and originally by Haxby et al., 2000): the 'rFFA' can be activated for faces independently of the 'rOFA', suggesting that the latter area, while being a critical component of the face cortical network, is not the necessary entry node of the network. This result has been replicated several times with the patient PS, also disclosing a pSTS response to faces (Sorgner et al., 2007). Importantly, it has also been replicated in another case of prosopagnosia with *bilateral* IOG lesions (Steeves et al., 2006), thus ruling out a possible contribution from the left hemisphere to the right 'FFA'. These observations suggest that there are direct pathways from early visual areas to the 'FFA', independent from the 'OFA', in line with DTI evidence (Kim et al., 2006). Thus, it qualifies the strict hierarchical face processing system as proposed by Ishai and others (Haxby et al., 2000; see also Jiang et al., 2006). Functionally, an early activation of the right 'FFA' may help in categorizing the stimulus as a face, based on a rapid integration of features at the basic level, a function that is largely preserved in prosopagnosic patients such as PS (Schiltz et al., 2006).

What is then the role of the right 'OFA', the area that is perhaps most often associated with prosopagnosia (Bouvier and Engel, 2006)? fMRI adaptation studies of the patient PS reveal that her

'rFFA' is unable to process individual faces normally: contrary to normal controls, the fMRI signal in the 'rFFA' is not significantly larger for different face identities than the same face identity repeated (Schiltz et al., 2006; Steeves et al., 2007; Dricot et al., *in press*, see Fig. 1B). Hence, without the contribution of the right 'OFA', the ipsilateral 'FFA' does not discriminate individual faces properly. It is thus tempting to suggest that a critical role of the right 'OFA', where neurons would presumably have smaller receptive fields than in the 'FFA', is to carry out finer-grained perceptual processes necessary to individualize faces. This is in line with recent evidence of impaired processing of individual face parts following TMS application to the right 'OFA' (Pitcher et al., 2007), but not with an interpretation of this result in favor of a strict hierarchical model, i.e. the 'OFA' preceding and leading to the 'FFA' activation. Rather, in the normal brain, the finer-grained perceptual analysis of faces in the 'rOFA' may be guided by the activation of a generic face template in the 'rFFA', so that both areas can develop an integrated representation of an *individual* face through reentrant interactions (Fig. 2). If this hypothesis is correct, discrimination of individual faces should increase the coupling between the 'FFA' and 'OFA', a hypothesis that could be tested using the dynamic causal modelling (DCM) approach of the face cortical network (Fairhall and Ishai, 2007), or effective connectivity methods without a priori constraints such as Granger causality mapping (GCM, Roebroeck et al., 2005).

To conclude, these observations carried out in single-cases of prosopagnosia allow refining and constraining the core section of the cortical network for face perception as proposed by Ishai along the lines of Haxby et al. (2000). They suggest an independent route from early visual areas to the 'FFA', and a critical role of reentrant interactions between the 'OFA' and 'FFA' in the right hemisphere for the elaboration for a full individual face percept. More generally, while this scheme is obviously still speculative and there are many questions about the whole dynamic cortical organization of face processing in the normal human brain that remain completely unresolved (e.g. the role and organization of the left hemisphere areas), these studies emphasize the complementary and inspiring role that single-cases studies of acquired prosopagnosic

patients can provide to functional neuroimaging, in order to clarify the cortical face network in the human brain.

### Acknowledgments

This work was supported by the Belgian National Research Foundation (FNRS). The author would like to thank Christine Schiltz as well as two anonymous reviewers for their precious comments on a previous version of this paper.

### References

- Barton, J.J., Press, D.Z., Keenan, J.P., O'Connor, M., 2002. Lesions of the fusiform face area impair perception of facial configuration in prosopagnosia. *Neurology* 58, 71–78.
- Bauer, R.M., 1986. The cognitive psychophysiology of prosopagnosia. In: Ellis, H.D., Jeeves, M.A., Newcombe, F., Young, A.W. (Eds.), *Aspects of Face Processing*. Martinus Nijhof publishers, Dordrecht, pp. 253–278.
- Bodamer, J., 1947. Die-Prosop-agnosie. *Arch. Psychiatr. Nervenkrankh.* 179, 6–54.
- Ellis, H.D., Florence, M., 1990. *Cogn. Neuropsychol.* 7, 81–105 (English translation by).
- Bouvier, S.E., Engel, S.A., 2006. Behavioral deficits and cortical damage loci in cerebral achromatopsia. *Cereb. Cortex* 16, 183–191.
- Bukach, C.M., Bub, D.N., Gauthier, I., Tarr, M.J., 2006. Perceptual expertise effects are not all or none: spatially limited perceptual expertise for faces in a case of prosopagnosia. *J. Cogn. Neurosci.* 18, 48–63.
- Damasio, A.R., Damasio, H., Van Hoesen, G.W., 1982. Prosopagnosia: anatomic basis and behavioral mechanisms. *Neurology* 32, 331–341.
- Damasio, A.R., Tranel, D., Damasio, H., 1990. Face agnosia and the neural substrates of memory. *Annu. Rev. Neurosci.* 13, 89–109.
- Dricot, L., Sorger, B., Schiltz, C., Goebel, R., Rossion, B., in press. The roles of “face” and “non-face” areas during individual face discrimination: evidence by fMRI adaptation in a brain-damaged prosopagnosic patient. *NeuroImage*.
- Farah, M.J., 1990. *Visual Agnosia: Disorders of Object Recognition and What They Tell Us About Normal Vision*. MIT Press Bradford Books.
- Fairhall, S.L., Ishai, A., 2007. Effective connectivity within the distributed cortical network for face perception. *Cereb. Cortex* 17, 2400–2406.
- Gainotti, G., Barbier, A., Marra, C., 2003. Slowly progressive defect in the recognition of familiar people in a patient with right anterior temporal atrophy. *Brain* 126, 792–803.
- Glover, G.H., Law, C.S., 2001. Spiral-in/out BOLD fMRI for increased SNR and reduced susceptibility artifacts. *Magn. Reson. Med.* 46, 515–522.
- Grill-Spector, K., Malach, R., 2001. fMRI-adaptation: a tool for studying the functional properties of human cortical neurons. *Acta Psychol. (Amst)* 107, 293–321.
- Gross, C.G., Rocha-Miranda, C.E., Bender, D.B., 1972. Visual properties of neurons in inferotemporal cortex of the macaque. *J. Neurophysiol.* 35, 96–111.
- Haxby, J.V., Hoffman, E.A., Gobbini, M.I., 2000. The distributed human neural system for face perception. *Trends Cogn. Sci.* 4, 223–233.
- Hécaen, H., Angelergues, R., 1962. Agnosia for faces (prosopagnosia). *Arch. Neurol.* 7, 92–100.
- Jiang, X., Rosen, E., Zeffiro, T., Vanmeter, J., Blanz, V., Riesenhuber, M., 2006. Evaluation of a shape-based model of human face discrimination using fMRI and behavioral techniques. *Neuron* 50, 159–172.
- Kim, M., Ducros, M., Carlson, T., Ronen, I., He, S., Ugurbil, K., Kim, D.S., 2006. Anatomical correlates of the functional organization in the human occipitotemporal cortex. *Magn. Reson. Imaging* 24, 583–590.
- Kleinschmidt, A., Cohen, L., 2006. The neural bases of prosopagnosia and pure alexia: recent insights from functional neuroimaging. *Curr. Opin. Neurol.* 19, 386–391.
- Kanwisher, N., McDermott, J., Chun, M.M., 1997. The fusiform face area: a module in human extrastriate cortex specialized for face perception. *J. Neurosci.* 17, 4302–4311.
- Mattson, A.J., Levin, H.S., Grafman, J., 2000. A case of prosopagnosia following moderate closed head injury with left hemisphere focal lesion. *Cortex* 36, 125–137.
- Michel, F., Poncet, M., Signoret, J.-L., 1989. Les lésions responsables de la prosopagnosie sont-elles toujours bilatérales? *Rev. Neurol.* 145, 764–770.
- Pitcher, D., Walsh, V., Yovel, G., Duchaine, B., 2007. TMS evidence for the involvement of the right occipital face area in early face processing. *Curr. Biol.* 17, 1–6.
- Price, C.J., Warburton, E.A., Moore, C.J., Frackowiak, R.S., Friston, K.J., 2001. Dynamic diaschisis: anatomically remote and context-sensitive human brain lesions. *J. Cogn. Neurosci.* 13, 419–429.
- Quaglino, A., Borelli, G., 1867. Emiplegia sinistra con amaurosi-guarigione-perdita totale della percezione dei colori e della memoria della configurazione degli oggetti. *Giornale d'Oftalmologia Italiano* 10, 106–117.
- Della Salla, S., Young, A.W., 2003. Quaglino's 1867 case of prosopagnosia. *Cortex* 39, 533–540 (English translation by).
- Roebroeck, A., Formisano, E., Goebel, R., 2005. Mapping directed influence over the brain using Granger causality and fMRI. *NeuroImage* 25, 230–242.
- Rossion, B., Caldara, R., Seghier, M., Schuller, A., Lazeyras, M., Mayer, F., 2003. A network of occipito-temporal face-sensitive areas besides the right middle fusiform gyrus is necessary for normal face processing. *Brain* 126, 2381–2395.
- Schiltz, C., Rossion, B., 2006. Faces are represented holistically in the human occipito-temporal cortex. *NeuroImage* 32, 1385–1394.
- Schiltz, C., Sorger, B., Caldara, R., Ahmed, F., Mayer, E., Goebel, R., Rossion, B., 2006. Impaired face discrimination in acquired prosopagnosia is associated with abnormal response to individual faces in the right middle fusiform gyrus. *Cereb. Cortex* 4, 574–586.
- Schweich, M., Bruyer, R., 1993. Heterogeneity in the cognitive manifestations of prosopagnosia—The study of a group of single cases. *Cogn. Neuropsychol.* 10, 529–547.
- Sergent, J., Signoret, J.-L., 1992. Varieties of functional deficits in prosopagnosia. *Cereb. Cortex* 2, 375–388.
- Sergent, J., Ohta, S., MacDonald, B., 1992. Functional neuroanatomy of face and object processing. A positron emission tomography study. *Brain* 115, 15–36.
- Sorger, B., Goebel, R., Schiltz, C., Rossion, B., 2007. Understanding the functional neuroanatomy of prosopagnosia. *NeuroImage* 35, 852–856.
- Steeves, J.K., Culham, J.C., Duchaine, B.C., Pratesi, C.C., Valyear, K.F., Schindler, I., Humphrey, G.K., Milner, A.D., Goodale, M.A., 2006. The fusiform face area is not sufficient for face recognition: evidence from a patient with dense prosopagnosia and no occipital face area. *Neuropsychologia* 44, 594–609.
- Steeves, J., Goltz, H., Dricot, L., Sorger, B., Peters, J., Goebel, R., Milner, A.D., Goodale, M.A., Rossion, B., 2007. Face-selective activation in the middle fusiform gyrus in a patient with acquired prosopagnosia: abnormal modulation for face identity. *J. Vis.* 7, 627.
- Tovée, M.J., 1998. Face processing: getting by with a little help from its friends. *Curr. Biol.* 8, R17–R320.
- Wright, H., Wardlaw, J., Young, A.W., Zeman, A., 2006. Prosopagnosia following nonconvulsive status epilepticus associated with a left fusiform gyrus malformation. *Epilepsy Behav.* 9, 197–220.